ESTTA Tracking number: **ESTTA776939**
Filing date: **10/15/2016**

IN THE UNITED STATES PATENT AND TRADEMARK OFFICE
BEFORE THE TRADEMARK TRIAL AND APPEAL BOARD

Petition for Cancellation

Notice is hereby given that the following party requests to cancel indicated registration.

Petitioner Information

Name	Nexderm, Inc.		
Entity	Corporation	Citizenship	California
Address	1849 W. Redlands Blvd., Ste. 102 Redlands, CA 92373 UNITED STATES		

Attorney information	Michael J. Sullivan 111 N. Market St., Suite 300 San Jose, CA 95113 UNITED STATES msullivan@mikesullivanlaw.com Phone:(408) 628-8882

Registration Subject to Cancellation

Registration No	4825438	Registration date	10/06/2015
Registrant	Lorita Holdings, LLC 756 N. Forest Drive Terre Haute, IN 47803 UNITED STATES		

Goods/Services Subject to Cancellation

Class 003. First Use: 2014/03/00 First Use In Commerce: 2014/03/00 All goods and services in the class are cancelled, namely: Body and beauty care cosmetics

Grounds for Cancellation

Priority and likelihood of confusion	Trademark Act Sections 14(1) and 2(d)

Mark Cited by Petitioner as Basis for Cancellation

U.S. Registration No.	3944027	Application Date	08/11/2010
Registration Date	04/12/2011	Foreign Priority Date	NONE
Word Mark	APEELE		

Design Mark	APEELE
Description of Mark	NONE
Goods/Services	Class 005. First use: First Use: 2010/07/19 First Use In Commerce: 2010/08/03 Medicated skin care preparations, namely, chemical solutions and topical creamsfor acne, photodamage, hyperpigmentation and rejuvenation of facial and body skin

Attachments	85105318#TMSN.png(bytes) Petition for Cancellation - AP-PEEL.pdf(118733 bytes) Exhibit 1 - APEELE Registration Status and Certificate.pdf(510105 bytes) Exhibit 2 - AP-PEEL Registration Status and Certificate.pdf(148555 bytes) Exhibit 3 - Definition of Cosmetic - Dictionary.com.pdf(131201 bytes) Exhibit 4 - Additional Definition of Cosmetic - The Free Dictionary.pdf(195367 bytes) Exhibit 5 - Acne vulgaris - Wikipedia.pdf(849086 bytes) Exhibit 6 - Photodamaged Skin - Dr. Joanna Day.pdf(197929 bytes) Exhibit 7 - Hyperpigmentation - Eucerin.pdf(1687495 bytes) Exhibit 8 - Rejuvenation - Ezine.pdf(255813 bytes)

Certificate of Service

The undersigned hereby certifies that a copy of this paper has been served upon all parties, at their address record by First Class Mail on this date.

Signature	/Michael J. Sullivan/
Name	Michael J. Sullivan
Date	10/15/2016

IN THE UNITED STATES PATENT AND TRADEMARK OFFICE
BEFORE THE TRADEMARK TRIAL AND APPEAL BOARD

In the Matter of Registration No. 4825438
Mark: **AP-PEEL**
Registered October 6, 2015

Nexderm, Inc., Petitioner, v. Lorita Holdings, LLC, Respondent.	Cancellation No.:

PETITION FOR CANCELLATION

Nexderm, Inc., a California corporation having an address of 1849 W. Redlands Blvd., Suite 102, Redlands, California 92373 ("Petitioner"), by its attorney, believes that it is damaged by the registration of AP-PEEL, Registration No. 4,825,438, issued on October 6, 2015, owned by Lorita Holdings, LLC, an Indiana limited liability company having an address of 756 N. Forest Drive, Terre Haute, Indiana 47803 ("Respondent"), and hereby petitions for cancellation of this registration.

The grounds for cancellation are as follows:

1. Petitioner is the owner of U.S. Trademark Registration No. 3,944,027 issued on April 12, 2011 for the mark APEELE in connection with "Medicated skin care preparations, namely, chemical solutions and topical creams for acne, photodamage, hyperpigmentation and rejuvenation of facial and body skin" in International Class 5 ("Petitioner's Registration"). Petitioner's Registration is now incontestable as a matter of law under Trademark Act

Section 15, 15 U.S.C. § 1065. A copy of the status and certificate for Petitioner's Registration is attached as Petitioner's Exhibit 1.

2. Petitioner's date of first use in commerce listed when applying for Petitioner's Registration is August 3, 2010. Petitioner has been using the mark on Petitioner's Registration in connection with the listed goods continuously since at least August 3, 2010.

3. Petitioner's APEELE mark is symbolic of the extensive goodwill established by Petitioner, has acquired a high degree of recognition through continued use and expenditures of time, effort and money in advertising and promotion, and serves as a unique identifier of the goods offered by Petitioner.

4. Respondent is the owner of U.S. Registration No. 4,825,438, issued on October 6, 2015 for AP-PEEL in connection with "Body and beauty care cosmetics" in International Class 3 ("Respondent's Registration"). A copy of the status and certificate for Respondent's Registration is attached as Petitioner's Exhibit 2.

5. Respondent's date of first use in commerce listed when applying for Respondent's Registration is March 2014.

6. Petitioner believes that the existence of Respondent's Registration on the Principal Register creates a likelihood of confusion among consumers that damages the value of Petitioner's Registration and its ability to use APEELE to effectively market to consumers.

7. Petitioner's mark has priority over Respondent's mark because Petitioner's date of first use in commerce for AP-PEEL and the date of issuance of Petitioner's Registration both pre-date Respondent's date of first use in commerce of APEELE.

8. Petitioner's mark, APEELE, and Respondent's mark, AP-PEEL, are identical in sound. On information and belief, most consumers upon a first encounter with Petitioner's mark,

APEELE, and Respondent's mark, AP-PEEL, would pronounce both marks the same way. Even if Respondent intends for its mark to be pronounced differently than Petitioner's mark, an identical pronunciation of both marks by consumers is both reasonable and likely.

9. Petitioner's mark, APEELE, and Respondent's mark, AP-PEEL, are spelled nearly identically, with Respondent's mark differing only in containing an additional internal "P", omitting the final "E", and containing a hyphen to separate the mark's two syllables.

10. The goods listed in Respondent's Registration are for "cosmetics." Cosmetics are substances that are applied to facial and body skin to improve appearance. Petitioner attaches two exemplary definitions of "cosmetics" in support of the above definition as Petitioner's Exhibits 3 and 4.

11. The goods listed in Petitioner's Registration are substances to be applied to "facial and body skin" to treat "acne, photodamage, [and] hyperpigmentation" and for the "rejuvenation" of such skin. Acne is a skin condition that negatively affects the appearance of skin, and therefore any preparation that treats acne, if such preparation is successful, improves the appearance of the skin just as a cosmetic would improve the skin's appearance. A definition of "acne" is attached as Petitioner's Exhibit 5. Photodamage is a skin condition that negatively affects the appearance of skin, and therefore any preparation that treats photodamage, if such preparation is successful, improves the appearance of the skin just as a cosmetic would improve the skin's appearance. A definition of "photodamage" is attached as Petitioner's Exhibit 6. Hyperpigmentation is a skin condition that negatively affects the appearance of skin, and therefore any preparation that treats hyperpigmentation, if such preparation is successful, improves the appearance of the skin just as a cosmetic would improve the skin's appearance. A definition of "hyperpigmentation" is attached as Petitioner's Exhibit 7. Finally, rejuvenation is a

treatment of the signs of aging to improve the appearance of skin. A definition of "rejuvenation" is attached as Petitioner's Exhibit 8.

12. As the goods listed on both Petitioner's Registration and Respondent's Registration are for products that are to be applied to skin in order to improve its appearance, Petitioner and Respondent are using their respective marks to sell highly similar products.

13. On information and belief, the goods sold respectively by Petitioner under the APEELE mark and by Respondent under the AP-PEEL mark are sold through the same channels of trade to the same class of consumers.

14. As Petitioner's mark and Respondent's mark are identical in pronunciation, nearly identical in appearance, are used by their respective owners to sell highly similar goods, and on information and belief are sold through the same channels of trade to the same class of consumers, the use of Respondent's mark is likely to cause confusion, mistake, and deception within the meaning of 15 U.S.C. § 1052(d).

15. This likelihood of confusion among consumers within the meaning of 15 U.S.C. § 1052(d) created by the use of Respondent's mark damages the value of Petitioner's Registration and limits Petitioner's ability to use APEELE to effectively market its goods to consumers.

16. As Petitioner's senior mark has priority over Respondent's junior mark, this likelihood of confusion created by the Respondent's junior mark should result in the cancellation of Respondent's Registration.

17. As, on information and belief, Petitioner will likely continue to suffer injury by the existence of Respondent's Registration, and as there exist the grounds alleged herein for cancellation of Respondent's Registration, Respondent's Registration should be canceled.

WHEREFORE, Petitioner prays that this Petition for Cancellation be sustained in favor of Petitioner and that U.S. Registration No. 4,825,438 be canceled.

Respectfully submitted,

Date: October 15, 2016

By: /Michael J. Sullivan/

Michael J. Sullivan
Law Office of Michael J. Sullivan
111 N. Market St., Suite 300
San Jose, CA 95113
msullivan@mikesullivanlaw.com

Attorney for Petitioner

CERTIFICATE OF SERVICE

I hereby certify that a true and complete copy of the foregoing Petition for Cancellation has been duly served on Derek W. Conner, counsel for Respondent Lorita Holdings, LLC, on October 15, 2016 via First Class U.S. Mail, postage prepaid to:

Derek W. Conner
Wright, Shagley & Lowery, P.C.
500 Ohio St.
Terre Haute, IN 47807-3517

/Michael J. Sullivan/
Michael J. Sullivan

Exhibit 1

Generated on: This page was generated by TSDR on 2016-10-15 18:35:39 EDT

Mark: APEELE

APEELE

US Serial Number:	85105318	**Application Filing Date:**	Aug. 11, 2010
US Registration Number:	3944027	**Registration Date:**	Apr. 12, 2011
Register:	Principal		
Mark Type:	Trademark		
Status:	Registered. The registration date is used to determine when post-registration maintenance documents are due.		
Status Date:	Apr. 12, 2011		
Publication Date:	Jan. 25, 2011		

Mark Information

Mark Literal Elements:	APEELE
Standard Character Claim:	Yes. The mark consists of standard characters without claim to any particular font style, size, or color.
Mark Drawing Type:	4 - STANDARD CHARACTER MARK

Goods and Services

Note: The following symbols indicate that the registrant/owner has amended the goods/services:

- Brackets [..] indicate deleted goods/services;
- Double parenthesis ((..)) identify any goods/services not claimed in a Section 15 affidavit of incontestability; and
- Asterisks *..* identify additional (new) wording in the goods/services.

For:	Medicated skin care preparations, namely, chemical solutions and topical creams for acne, photodamage, hyperpigmentation and rejuvenation of facial and body skin		
International Class(es):	005 - Primary Class	**U.S Class(es):**	006, 018, 044, 046, 051, 052
Class Status:	ACTIVE		
Basis:	1(a)		
First Use:	Jul. 19, 2010	**Use in Commerce:**	Aug. 03, 2010

Basis Information (Case Level)

Filed Use:	Yes	**Currently Use:**	Yes	**Amended Use:**	No
Filed ITU:	No	**Currently ITU:**	No	**Amended ITU:**	No
Filed 44D:	No	**Currently 44D:**	No	**Amended 44D:**	No
Filed 44E:	No	**Currently 44E:**	No	**Amended 44E:**	No
Filed 66A:	No	**Currently 66A:**	No		
Filed No Basis:	No	**Currently No Basis:**	No		

Current Owner(s) Information

Owner Name:	NEXDERM, INC.		
Owner Address:	1849 W. REDLANDS BLVD., SUITE 102 REDLANDS, CALIFORNIA 92373 UNITED STATES		
Legal Entity Type:	CORPORATION	**State or Country Where Organized:**	CALIFORNIA

Attorney/Correspondence Information

Attorney of Record

Attorney Name: Michael J. Sullivan

Attorney Primary Email Address: msullivan@mikesullivanlaw.com

Attorney Email Authorized: Yes

Correspondent

Correspondent Name/Address: Michael J. Sullivan
Law Office of Michael J. Sullivan
111 N. Market St., Ste. 300
San Jose, CALIFORNIA 95113
UNITED STATES

Phone: (408) 628-8882

Correspondent e-mail: msullivan@mikesullivanlaw.com mseraj@nexderm.com

Correspondent e-mail Authorized: Yes

Domestic Representative - Not Found

Prosecution History

Date	Description	Proceeding Number
Sep. 28, 2016	TEAS SECTION 8 & 15 RECEIVED	
Aug. 08, 2016	ATTORNEY REVOKED AND/OR APPOINTED	
Aug. 08, 2016	TEAS REVOKE/APPOINT ATTORNEY RECEIVED	
Apr. 12, 2016	COURTESY REMINDER - SEC. 8 (6-YR) E-MAILED	
Nov. 04, 2015	AUTOMATIC UPDATE OF ASSIGNMENT OF OWNERSHIP	
May 27, 2012	TEAS CHANGE OF CORRESPONDENCE RECEIVED	
Apr. 12, 2011	REGISTERED-PRINCIPAL REGISTER	
Jan. 25, 2011	OFFICIAL GAZETTE PUBLICATION CONFIRMATION E-MAILED	
Jan. 25, 2011	PUBLISHED FOR OPPOSITION	
Dec. 22, 2010	LAW OFFICE PUBLICATION REVIEW COMPLETED	68552
Dec. 22, 2010	ASSIGNED TO LIE	68552
Dec. 01, 2010	APPROVED FOR PUB - PRINCIPAL REGISTER	
Nov. 29, 2010	ASSIGNED TO EXAMINER	77762
Aug. 16, 2010	NEW APPLICATION OFFICE SUPPLIED DATA ENTERED IN TRAM	
Aug. 14, 2010	NEW APPLICATION ENTERED IN TRAM	

TM Staff and Location Information

TM Staff Information - None

File Location

Current Location: PUBLICATION AND ISSUE SECTION

Date in Location: Apr. 12, 2011

Assignment Abstract Of Title Information

Summary

Total Assignments: 1

Registrant: Ascend Pharmaceuticals, Inc.

Assignment 1 of 1

Conveyance: ASSIGNS THE ENTIRE INTEREST

Reel/Frame: 5653/0498

Pages: 7

Date Recorded: Oct. 27, 2015

Supporting Documents: assignment-tm-5653-0498.pdf

Assignor

Name: ASCEND PHARMACEUTICALS, INC.

Execution Date: Oct. 23, 2015

Legal Entity Type: CORPORATION

State or Country Where Organized: CALIFORNIA

Assignee			
Name:	NEXDERM, INC.		
Legal Entity Type:	CORPORATION	**State or Country Where Organized:**	CALIFORNIA
Address:	1849 W. REDLANDS BLVD., SUITE 102 REDLANDS, CALIFORNIA 92373		

Correspondent	
Correspondent Name:	MICHAEL J. SULLIVAN
Correspondent Address:	111 N. MARKET ST., SUITE 300 SAN JOSE, CA 95113

Domestic Representative - Not Found

United States of America

United States Patent and Trademark Office

APEELE

Reg. No. 3,944,027

Registered Apr. 12, 2011

Int. Cl.: 5

TRADEMARK

PRINCIPAL REGISTER

ASCEND PHARMACEUTICALS, INC. (CALIFORNIA CORPORATION)
1849 W. REDLANDS BLVD., SUITE 102
REDLANDS, CA 92373

FOR: MEDICATED SKIN CARE PREPARATIONS, NAMELY, CHEMICAL SOLUTIONS AND TOPICAL CREAMS FOR ACNE, PHOTODAMAGE, HYPERPIGMENTATION AND REJUVENATION OF FACIAL AND BODY SKIN, IN CLASS 5 (U.S. CLS. 6, 18, 44, 46, 51 AND 52).

FIRST USE 7-19-2010; IN COMMERCE 8-3-2010.

THE MARK CONSISTS OF STANDARD CHARACTERS WITHOUT CLAIM TO ANY PARTICULAR FONT, STYLE, SIZE, OR COLOR.

SER. NO. 85-105,318, FILED 8-11-2010.

KELLY BOULTON, EXAMINING ATTORNEY

David J. Kappos

Director of the United States Patent and Trademark Office

Exhibit 2

Generated on: This page was generated by TSDR on 2016-10-15 18:34:29 EDT

Mark: AP-PEEL

Ap-peel

US Serial Number:	86443803	**Application Filing Date:**	Nov. 04, 2014
US Registration Number:	4825438	**Registration Date:**	Oct. 06, 2015
Filed as TEAS Plus:	Yes	**Currently TEAS Plus:**	Yes
Register:	Principal		
Mark Type:	Trademark		
TM5 Common Status Descriptor:	LIVE/REGISTRATION/Issued and Active The trademark application has been registered with the Office.		
Status:	Registered. The registration date is used to determine when post-registration maintenance documents are due.		
Status Date:	Oct. 06, 2015		
Publication Date:	Apr. 14, 2015		

Mark Information

Mark Literal Elements:	AP-PEEL
Standard Character Claim:	Yes. The mark consists of standard characters without claim to any particular font style, size, or color.
Mark Drawing Type:	4 - STANDARD CHARACTER MARK

Goods and Services

Note: The following symbols indicate that the registrant/owner has amended the goods/services:

- Brackets [..] indicate deleted goods/services;
- Double parenthesis ((..)) identify any goods/services not claimed in a Section 15 affidavit of incontestability; and
- Asterisks *..* identify additional (new) wording in the goods/services.

For:	Body and beauty care cosmetics		
International Class(es):	003 - Primary Class	**U.S Class(es):**	001, 004, 006, 050, 051, 052
Class Status:	ACTIVE		
Basis:	1(a)		
First Use:	Mar. 2014	**Use in Commerce:**	Mar. 2014

Basis Information (Case Level)

Filed Use:	Yes	**Currently Use:**	Yes	**Amended Use:**	No
Filed ITU:	No	**Currently ITU:**	No	**Amended ITU:**	No
Filed 44D:	No	**Currently 44D:**	No	**Amended 44D:**	No
Filed 44E:	No	**Currently 44E:**	No	**Amended 44E:**	No
Filed 66A:	No	**Currently 66A:**	No		
Filed No Basis:	No	**Currently No Basis:**	No		

Current Owner(s) Information

Owner Name: Lorita Holdings, LLC

Owner Address: 756 N. Forest Drive
Terre Haute, INDIANA UNITED STATES 47803

Legal Entity Type: LIMITED LIABILITY COMPANY

State or Country Where Organized: INDIANA

Attorney/Correspondence Information

Attorney of Record

Attorney Name: Derek W. Conner

Attorney Primary Email Address: dconner@wslfirm.com

Attorney Email Authorized: Yes

Correspondent

Correspondent Name/Address: DEREK W. CONNER
WRIGHT, SHAGLEY & LOWERY, P.C.
500 OHIO ST
TERRE HAUTE, INDIANA UNITED STATES 47807-3517

Phone: 812-232-3388

Fax: 812-232-8817

Correspondent e-mail: dconner@wslfirm.com

Correspondent e-mail Authorized: Yes

Domestic Representative - Not Found

Prosecution History

Date	Description	Proceeding Number
Oct. 06, 2015	REGISTERED-PRINCIPAL REGISTER	
Aug. 28, 2015	EXTENSION OF TIME TO OPPOSE PROCESS - TERMINATED	
Apr. 14, 2015	EXTENSION OF TIME TO OPPOSE RECEIVED	
Apr. 15, 2015	LETTER OF PROTEST EVIDENCE REVIEWED	82103
Apr. 14, 2015	LETTER OF PROTEST ACCEPTED	
Apr. 14, 2015	OFFICIAL GAZETTE PUBLICATION CONFIRMATION E-MAILED	
Apr. 14, 2015	PUBLISHED FOR OPPOSITION	
Mar. 25, 2015	NOTIFICATION OF NOTICE OF PUBLICATION E-MAILED	
Mar. 02, 2015	APPROVED FOR PUB - PRINCIPAL REGISTER	
Feb. 24, 2015	ASSIGNED TO EXAMINER	82103
Nov. 15, 2014	NOTICE OF PSEUDO MARK E-MAILED	
Nov. 14, 2014	NEW APPLICATION OFFICE SUPPLIED DATA ENTERED IN TRAM	
Nov. 07, 2014	NEW APPLICATION ENTERED IN TRAM	

TM Staff and Location Information

TM Staff Information - None

File Location

Current Location: PUBLICATION AND ISSUE SECTION

Date in Location: Oct. 06, 2015

Proceedings

Summary

Number of Proceedings: 1

Type of Proceeding: Extension of Time

Proceeding Number: 86443803

Filing Date: Apr 14, 2015

Status: Terminated

Status Date: Aug 28, 2015

Interlocutory Attorney:

Defendant

Name: Lorita Holdings, LLC

Correspondent Address: DEREK W. CONNER
WRIGHT, SHAGLEY & LOWERY, P.C.
500 OHIO ST
TERRE HAUTE IN UNITED STATES , 47807-3517

Associated marks

Mark	Application Status	Serial Number	Registration Number
AP-PEEL	Registered	86443803	4825438

Potential Opposer(s)

Name: Ascend Pharmaceuticals, Inc.

Correspondent Address: Michael J. Sullivan
Law Office of Michael J. Sullivan
111 N. Market St., Suite 300
San Jose CA UNITED STATES , 95113

Correspondent e-mail: msullivan@mikesullivanlaw.com

Prosecution History

Entry Number	History Text	Date	Due Date
1	INCOMING - EXT TIME TO OPPOSE FILED	Apr 14, 2015	
2	EXTENSION OF TIME GRANTED	Apr 14, 2015	

United States of America

United States Patent and Trademark Office

Ap-peel

Reg. No. 4,825,438

Registered Oct. 6, 2015

Int. Cl.: 3

TRADEMARK

PRINCIPAL REGISTER

LORITA HOLDINGS, LLC (INDIANA LIMITED LIABILITY COMPANY)
756 N. FOREST DRIVE
TERRE HAUTE, IN 47803

FOR: BODY AND BEAUTY CARE COSMETICS, IN CLASS 3 (U.S. CLS. 1, 4, 6, 50, 51 AND 52).

FIRST USE 3-0-2014; IN COMMERCE 3-0-2014.

THE MARK CONSISTS OF STANDARD CHARACTERS WITHOUT CLAIM TO ANY PARTICULAR FONT, STYLE, SIZE, OR COLOR.

SER. NO. 86-443,803, FILED 11-4-2014.

KATHERINE E. HALMEN, EXAMINING ATTORNEY

Michelle K. Lee

Director of the United States
Patent and Trademark Office

REQUIREMENTS TO MAINTAIN YOUR FEDERAL TRADEMARK REGISTRATION

WARNING: YOUR REGISTRATION WILL BE CANCELLED IF YOU DO NOT FILE THE DOCUMENTS BELOW DURING THE SPECIFIED TIME PERIODS.

Requirements in the First Ten Years*
What and When to File:

First Filing Deadline: You must file a Declaration of Use (or Excusable Nonuse) between the 5th and 6th years after the registration date. *See* 15 U.S.C. §§1058, 1141k. If the declaration is accepted, the registration will continue in force for the remainder of the ten-year period, calculated from the registration date, unless cancelled by an order of the Commissioner for Trademarks or a federal court.

Second Filing Deadline: You must file a Declaration of Use (or Excusable Nonuse) **and** an Application for Renewal between the 9th and 10th years after the registration date.* *See* 15 U.S.C. §1059.

Requirements in Successive Ten-Year Periods*
What and When to File:

You must file a Declaration of Use (or Excusable Nonuse) **and** an Application for Renewal between every 9th and 10th-year period, calculated from the registration date.*

Grace Period Filings*

The above documents will be accepted as timely if filed within six months after the deadlines listed above with the payment of an additional fee.

***ATTENTION MADRID PROTOCOL REGISTRANTS:** The holder of an international registration with an extension of protection to the United States under the Madrid Protocol must timely file the Declarations of Use (or Excusable Nonuse) referenced above directly with the United States Patent and Trademark Office (USPTO). The time periods for filing are based on the U.S. registration date (not the international registration date). The deadlines and grace periods for the Declarations of Use (or Excusable Nonuse) are identical to those for nationally issued registrations. *See* 15 U.S.C. §§1058, 1141k. However, owners of international registrations do not file renewal applications at the USPTO. Instead, the holder must file a renewal of the underlying international registration at the International Bureau of the World Intellectual Property Organization, under Article 7 of the Madrid Protocol, before the expiration of each ten-year term of protection, calculated from the date of the international registration. *See* 15 U.S.C. §1141j. For more information and renewal forms for the international registration, see http://www.wipo.int/madrid/en/.

NOTE: Fees and requirements for maintaining registrations are subject to change. Please check the USPTO website for further information. With the exception of renewal applications for registered extensions of protection, you can file the registration maintenance documents referenced above online at http://www.uspto.gov.

NOTE: A courtesy e-mail reminder of USPTO maintenance filing deadlines will be sent to trademark owners/holders who authorize e-mail communication and maintain a current e-mail address with the USPTO. To ensure that e-mail is authorized and your address is current, please use the Trademark Electronic Application System (TEAS) Correspondence Address and Change of Owner Address Forms available at http://www.uspto.gov.

Exhibit 3

cosmetic [koz-**met**-ik]

Examples Word Origin

noun

1. a powder, lotion, lipstick, rouge, or other preparation forbeautifying the face, skin, hair, nails, etc.

2. **cosmetics,** superficial measures to make something appearbetter, more attractive, or more impressive:
   The budget committee opted for cosmetics instead of a seriousurban renewal plan.

adjective

3. serving to beautify; imparting or improving beauty, especially ofthe face.

4. used or done superficially to make something look better, moreattractive, or more impressive:
   Alterations in the concert hall were only cosmetic and did nothingto improve the acoustics.

Origin

Greek

1595-1605

1595-
1605; < Greek *kosmētikós* relating to adornment, equivalent to*kosmēt* (*ós*) adorned, arranged (verbid of *kosmeîn,* derivative of*kósmos* order, a
ikos -ic

Related forms

cosmetically, adverb

anticosmetics, adjective

Dictionary.com Unabridged
Based on the Random House Dictionary, © Random House, Inc. 2015.
Cite This Source

Examples from the web for cosmetic

Some of her patients had previously worn dust masks colored with*cosmetic* foundation.

Hair tonics, perfumes, toilet waters and other *cosmetic* products weresimilarly exempt.

Species found in the deep sea are used as additives in *cosmetic*products and also in food.

British Dictionary definitions for cosmetic

cosmetic /kɒzˈmɛtɪk/

noun

1. any preparation applied to the body, esp the face, with theintention of beautifying it

adjective

2. serving or designed to beautify the body, esp the face

3. having no other function than to beautify: *cosmetic illustrations ina book*

4. (**derogatory**) designed to cover up a greater flaw or deficiency;superficial: *their resignation is a cosmetic exercise*

Derived Forms

cosmetically, adverb
cosmeticology, noun

Word Origin

C17: from Greek *kosmētikos,* from *kosmein* to arrange, from *kosmos*order

Collins English Dictionary - Complete & Unabridged 2012 Digital Edition
© William Collins Sons & Co. Ltd. 1979, 1986 © HarperCollins
Publishers 1998, 2000, 2003, 2005, 2006, 2007, 2009, 2012
Cite This Source

Word Origin and History for cosmetic

n.

c.1600, "art of beautifying," from Latinized form of Greek *kosmetike(tekhne)* "the art of dress and ornament," from fem. of *kosmetikos*(see cosr

adj.

1640s, from French *cosmétique* (16c.), from Greek *kosmetikos*"skilled in adornment or arrangement," from *kosmein* "to arrange,adorn," from *ko*

Online Etymology Dictionary, © 2010 Douglas Harper
Cite This Source

cosmetic in Medicine

cosmetic cos·met·ic (kŏz-mĕt'ĭk)
n.

A preparation, such as powder or a skin cream, designed to beautify thebody by direct application. *adj.*

1. Serving to beautify the body, especially the face and hair.
2. Serving to modify or improve the appearance of a physical feature,defect, or irregularity.

The American Heritage® Stedman's Medical Dictionary
Copyright © 2002, 2001, 1995 by Houghton Mifflin Company. Published by Houghton Mifflin Company.

Exhibit 4

cosmetic - definition of cosmetic by The Free Dictionary

http://www.thefreedictionary.com/cosmetic

cosmetic

Also found in: **Medical**, **Encyclopedia**, **Wikipedia**.

cos·met·ic (kŏz-mĕt′ĭk)

n.

1. A preparation, such as powder or a skin cream, designed to beautify the body by direct application.
2. Something superficial that is used to cover a deficiency or defect.

adj.

1. Serving to beautify the body, especially the face and hair.
2. Serving to modify or improve the appearance of a bodily feature, defect, or irregularity: *cosmetic therapy.*
3.
   a. Decorative rather than functional: *cosmetic fenders on cars.*
   b. Lacking depth or significance; superficial: *made a few cosmetic changes when she took over the company.*

[French cosmétique, from Greek kosmētikos, *skilled in arranging*, from kosmētos, *well-ordered*, from kosmein, *to arrange*, from kosmos, *order*.]

cos·met′i·cal·ly *adv.*

American Heritage® Dictionary of the English Language, Fifth Edition. Copyright © 2011 by Houghton Mifflin Harcourt Publishing Company. Published by Houghton Mifflin Harcourt Publishing Company. All rights reserved.

cosmetic (kɒzˈmɛtɪk)

n

1. any preparation applied to the body, esp the face, with the intention of beautifying it

adj

2. serving or designed to beautify the body, esp the face
3. having no other function than to beautify: *cosmetic illustrations in a book*.
4. designed to cover up a greater flaw or deficiency; superficial: *their resignation is a cosmetic exercise*.

[C17: from Greek *kosmētikos,* from *kosmein* to arrange, from *kosmos* order]

cosˈmetically *adv* **cosˌmetiˈcology** *n*

Collins English Dictionary – Complete and Unabridged © HarperCollins Publishers 1991, 1994, 1998, 2000, 2003

cos•met•ic (kɒzˈmɛt ɪk)

n.

1. a powder, lotion, cream, or other preparation for beautifying the face, skin, hair, nails, etc.
2. **cosmetics,** superficial measures to make something seem better than it is.

adj.

3. serving to impart or improve beauty, esp. of the face: *cosmetic surgery.*

4. used or done superficially to make something seem better than it is.

[1595–1605; < Greek *kosmētikós* relating to adornment =*kosmēt(ós),* v. adj. of *kosmeîn* to order, adorn, derivative of *kósmos* order, adornment + *-ikos* **-ic**]

cos•met′i•cal•ly, *adv.*

Random House Kernerman Webster's College Dictionary, © 2010 K Dictionaries Ltd. Copyright 2005, 1997, 1991 by Random House, Inc. All rights reserved.

Thesaurus

Legend: ≡ Synonyms ↔ Related Words ≠ Antonyms

Noun 1. cosmetic - a toiletry designed to beautify the body

↔ **depilator**, **epilator**, **depilatory** - a cosmetic for temporary removal of undesired hair

↔ **highlighter** - a cosmetic used to highlight the eyes or cheekbones

↔ **makeup**, **make-up**, **war paint** - cosmetics applied to the face to improve or change your appearance

↔ **nail enamel**, **nail polish**, **nail varnish** - a cosmetic lacquer that dries quickly and that is applied to the nails to color them or make them shiny

↔ **pencil** - a cosmetic in a long thin stick; designed to be applied to a particular part of the face; "an eyebrow pencil"

↔ **toilet articles**, **toiletry** - artifacts used in making your toilet (washing and taking care of your body)

Adj. 1. cosmetic - serving an esthetic rather than a useful purpose; "cosmetic fenders on cars"; "the buildings were utilitarian rather than decorative"

≡ **decorative**, **ornamental**

↔ **nonfunctional** - not having or performing a function

2. cosmetic - serving an aesthetic purpose in beautifying the body; "cosmetic surgery"; "enhansive makeup"

≡ **enhancive**

↔ **aesthetical**, **esthetic**, **esthetical**, **aesthetic** - concerning or characterized by an appreciation of beauty or good taste; "the aesthetic faculties"; "an aesthetic person"; "aesthetic feeling"; "the illustrations made the book an aesthetic success"

Based on WordNet 3.0, Farlex clipart collection. © 2003-2012 Princeton University, Farlex Inc.

cosmetic

adjective ≡ **superficial**, **surface**, touching-up, **nonessential** *It is a cosmetic measure which will not help the situation in the long run.*

Collins Thesaurus of the English Language – Complete and Unabridged 2nd Edition. 2002 © HarperCollins Publishers 1995, 2002

Translations

Select a language: Spanish / Español

cosmetic [kɒzˈmetɪk]

A. *ADJ* → **cosmético**

the changes are merely cosmetic (*fig*) → los **cambios** son **puramente cosméticos**

B. *N* (*often pl*) → **cosmético** *m*

C. *CPD* **cosmetic preparation** *N* → **cosmético** *m*

cosmetic surgery *N* → **cirugía** *f* **estética**

Collins Spanish Dictionary - Complete and Unabridged 8th Edition 2005 © William Collins Sons & Co. Ltd. 1971, 1988 © HarperCollins Publishers 1992, 1993, 1996, 1997, 2000, 2003, 2005

cosmetic (kozˈmetik) *adjective*

designed to increase the beauty and hide the defects of something, *especially* the face. *She had cosmetic surgery to improve the shape of her nose.*

cosmético

noun

a preparation for this purpose. *She's quite pretty – she does not need to wear so many cosmetics (= lipstick, eye-shadow etc).*

cosmético

cosmetician (ˈkozmətiʃən) *noun*

cosmetólogo

Kernerman English Multilingual Dictionary © 2006-2013 **K Dictionaries Ltd**.

cos·met·ic

n. cosmético;

a. cósmetico-a.

English-Spanish Medical Dictionary © Farlex 2012

cosmetic *adj & n* cosmético

English-Spanish/Spanish-English Medical Dictionary Copyright © 2006 by The McGraw-Hill Companies, Inc. All rights reserved.

| **Copyright © 2003-2015 Farlex, Inc**

Disclaimer

All content on this website, including dictionary, thesaurus, literature, geography, and other reference data is for informational purposes only. This information should not be considered complete, up to date, and is not intended to be used in place of a visit, consultation, or advice of a legal, medical, or any other professional.

A Mode Tend Parenting Partnership

Exhibit 5

Acne vulgaris

From Wikipedia, the free encyclopedia

Acne vulgaris (or simply **acne**) is a chronic skin condition characterized by areas of blackheads, whiteheads, pimples, greasy skin, and possibly scarring.[1][2] The resulting appearance may lead to anxiety, reduced self-esteem, and in extreme cases, depression or thoughts of suicide.[3][4]

Acne vulgaris

Acne in a 14-year-old male during puberty

Classification and external resources

ICD-10	L70.0 (http://apps.who.int/classifications/icd10/browse/2015/en#/L70.0)
ICD-9	706.1 (http://www.icd9data.com/getICD9Code.ashx?icd9=706.1)
DiseasesDB	10765 (http://www.diseasesdatabase.com/ddb10765.htm)
MedlinePlus	000873 (http://www.nlm.nih.gov/medlineplus/ency/article/000873.htm)
eMedicine	derm/2 (http://www.emedicine.com/derm/topic2.htm)
Patient UK	Acne vulgaris (http://www.patient.co.uk/doctor/acne-vulgaris)
MeSH	D000152 (https://www.nlm.nih.gov/cgi/mesh/2015/MB_cgi?field=uid&term=D000152)

Genetics is estimated to be the cause of 80% of cases.[2] The role of diet as a cause is unclear.[2] Neither cleanliness nor sunlight appear to be involved.[2] However, cigarette smoking does increase the risk of developing acne and worsens its severity.[5] Acne mostly affects skin with a greater number of oil glands including the face, upper part of the chest, and back.[6] During puberty in both sexes, acne is often brought on by an increase in androgens such as testosterone.[7]

Many treatment options are available to improve the appearance of acne including lifestyle changes, procedures, and medications. Eating fewer simple carbohydrates like sugar may help.[8] Topical benzoyl peroxide, salicylic acid, and azelaic acid are commonly used treatments.[9] Antibiotics and retinoids are available topically and by mouth to treat acne.[9] However, resistance to antibiotics may develop.[10] A number of birth control pills may be useful in women.[9] Oral isotretinoin is usually reserved for severe acne due to greater potential side effects.[9] Early and aggressive treatment is advocated by some to lessen the overall long-term impact to individuals.[4]

Acne occurs most commonly during adolescence, affecting an estimated 80–90% of teenagers in the Western world.[11][12][13] Lower rates are reported in some rural societies.[13][14] In 2010, acne was estimated to affect 650 million people globally making it the 8th most common disease worldwide.[15]

People may also be affected before and after puberty.[16] Though it becomes less common in adulthood than in adolescence, nearly half of people in their twenties and thirties continue to have acne.[2] About 4% continue to have difficulties into their forties.[2]

Contents

- 1 Classification
- 2 Signs and symptoms
  - 2.1 Scars
  - 2.2 Pigmentation
- 3 Cause
  - 3.1 Genetic
  - 3.2 Hormonal
  - 3.3 Infectious
  - 3.4 Lifestyle
  - 3.5 Psychological
- 4 Pathophysiology
- 5 Diagnosis
  - 5.1 Differential diagnosis
- 6 Management
  - 6.1 Medications
  - 6.2 Procedures
  - 6.3 Alternative medicine
- 7 Prognosis
- 8 Epidemiology
- 9 History
- 10 Society and culture
  - 10.1 Cost
  - 10.2 Stigma
- 11 Research
- 12 References
- 13 External links

Classification

Acne is commonly classified by severity as mild, moderate, or severe. This type of categorization can be an important factor in determining the appropriate treatment regimen.[12] Mild acne is classically defined as open (blackheads) and closed comedones (whiteheads) limited to the face with occasional inflammatory lesions.[12] Acne may be considered to be of moderate severity when a higher number of inflammatory papules and pustules occur on the face compared to mild cases of acne and acne lesions also occur on the trunk of the body.[12] Lastly, severe acne is said to occur when nodules and cysts are the characteristic facial lesions and involvement of the trunk is extensive.[12]

Signs and symptoms

Typical features of acne include seborrhea (increased oil secretion), microcomedones, comedones, papules, pustules, nodules (large papules), and possibly scarring.[1][17] The appearance of acne varies with skin color. It may result in psychological and social problems.[12]

Some of the large nodules were previously called cysts and the term *nodulocystic* has been used to describe severe cases of inflammatory acne.[18]

Scars

Acne scars are the result of inflammation within the dermal layer of skin brought on by acne and are estimated to affect 95% of people with acne vulgaris.[19] The scar is created by an abnormal form of healing following this dermal inflammation.[19] Scarring is most likely to occur with severe nodulocystic acne, but may occur with any form of acne vulgaris.[19] Acne scars are classified based on whether the abnormal healing response following dermal inflammation leads to excess collagen deposition or collagen loss at the site of the acne lesion.[19]

Atrophic acne scars are the most common type of acne scar and have lost collagen from this healing response.[19] Atrophic scars may be further classified as ice-pick scars, boxcar scars, and rolling scars.[19] Ice pick scars are typically described as narrow (less than 2 mm across), deep scars that extend into the dermis.[19] Rolling scars are wider than ice pick scars (4–5 mm across) and have a wave-like pattern of depth in the skin.[19] Boxcar scars are round or ovoid indented scars with sharp borders and vary in size from 1.5–4 mm across.[19]

Hypertrophic scars are less common and are characterized by increased collagen content after the abnormal healing response.[19] They are described as firm and raised from the skin.[19][20] Hypertrophic scars remain within the original margins of the wound whereas keloid scars can form scar tissue outside of these borders.[19] Keloid scars from acne usually occur in men and on the trunk of the body rather than the face.[19]

Pigmentation

Postinflammatory hyper pigmentation (PIH) is usually the result of nodular or cystic acne (the painful 'bumps' lying under the skin). They often leave behind an inflamed red mark after the original acne lesion has resolved. PIH occurs more often in people with darker skin color.[21] Pigmented scar is a common but misleading term, as it suggests the color change is permanent. Often, PIH can be avoided by avoiding aggravation of the nodule or cyst. These scars can fade with time. However, untreated scars can last for months, years, or even be permanent if deeper layers of skin are affected.[22] Daily use of SPF 15 or higher sunscreen can minimize pigmentation associated with acne.[22]

A severe case of cystic acne

Cystic acne on the back.

Acne vulgaris types: A: Facial cystic acne, B: Subsiding tropical acne of trunk, C: Extensive chest and shoulder acne.

Cause

Genetic

The predisposition for specific individuals to acne is likely explained in part by a genetic component, which has been supported by twin studies as well as studies that have looked at rates of acne among first degree relatives.[23] The genetics of acne susceptibility is likely polygenic, as the disease does not follow classic Mendelian inheritance pattern. There are multiple candidates for genes which are possibly related to acne, including polymorphisms in TNF-alpha, IL-1 alpha, and CYP1A1 among others.[11]

Hormonal

Hormonal activity, such as menstrual cycles and puberty, may contribute to the formation of acne. During puberty, an increase in sex hormones called androgens cause the follicular glands to grow larger and make more sebum.[6][24] A similar increase in androgens occurs during pregnancy, also leading to increased sebum production.[25]

Several hormones have been linked to acne including the androgens testosterone, dihydrotestosterone (DHT) and dehydroepiandrosterone sulfate (DHEAS), as well as insulin-like growth factor 1 (IGF-I) and growth hormone.[26] Use of anabolic steroids may have a similar effect.[27]

Acne that develops between the ages of 21 and 25 is uncommon.[28] True acne vulgaris in adult women may be due to pregnancy or polycystic ovary syndrome.[29]

Infectious

Propionibacterium acnes (*P. acnes*) is the anaerobic bacterium species that is widely suspected to contribute to the development of acne, but its exact role in this process is not entirely clear.[23][30] There are specific sub-strains of *P. acnes* associated with normal skin and others with long-term acne. It is unclear whether these undesirable strains evolve on-site or are acquired, or possibly both depending on the person. These strains either have the capability of changing, perpetuating, or adapting to, the abnormal cycle of inflammation, oil production, and inadequate sloughing of acne pores. One particularly virulent strain, has been circulating in Europe for at least 87 years.[31] Infection with the parasitic mite *Demodex* is associated with the development of acne.[17][32] However, it is unclear if eradication of these mites improves acne.[32]

Lifestyle

Cigarette smoking is known to increase the risk of developing acne.[5] Additionally, acne severity worsens as the number of cigarettes a person smokes increases.[5] The relationship between diet and acne is unclear as there is no high-quality evidence.[33] However, a high glycemic load diet is associated with worsening acne.[8][34] There is weak evidence of a positive association between the consumption of milk and a greater rate and severity of acne.[32][35][36][37] Other associations such as chocolate and salt are not supported by the evidence.[35] Chocolate does contain a varying amount of sugar that can lead to a high glycemic load and it can be made with or without milk. There may be a relationship between acne and insulin metabolism and one trial found a relationship between acne and obesity.[38] Vitamin B12 may trigger acneiform eruptions, or exacerbate existing acne, when taken in doses exceeding the recommended daily intake.[39]

Psychological

While the connection between acne and stress has been debated, research indicates that increased acne severity is associated with high stress levels.[40][41]

Pathophysiology

Acne develops as a result of blockages in the follicles. The earliest pathologic changes are the excessive deposition of the protein keratin and oily sebum in the hair follicle resulting in the formation of a plug (a microcomedo).[6] During adrenarche, a higher level of the androgen (DHEA-S) results in the enlargement of the sebaceous glands and increases sebum production. A microcomedo may enlarge to form an open comedo (blackhead) or closed comedo. The dark color of a blackhead occurs due to oxidation of the skin pigment melanin.[12]

Comedones result from the clogging of sebaceous glands with sebum, a naturally occurring oil, and dead skin cells.[6] In these conditions, the naturally occurring largely commensal bacterium *Propionibacterium acnes* can cause inflammation within and around the follicle, leading to inflammatory lesions (papules,

infected pustules, or nodules) in the dermis around the microcomedo or comedone, which results in redness and may result in scarring or hyperpigmentation.[6][42][43] Severe acne is inflammatory, but acne can also be noninflammatory.[28]

Diagnosis

There are multiple scales for grading the severity of acne vulgaris,[44] three of these being:

- Leeds acne grading technique: Counts and categorizes lesions into inflammatory and non-inflammatory (ranges from 0–10.0).
- Cook's acne grading scale: Uses photographs to grade severity from 0 to 8 (0 being the least severe and 8 being the most severe).
- Pillsbury scale: Simply classifies the severity of the acne from 1 (least severe) to 4 (most severe).

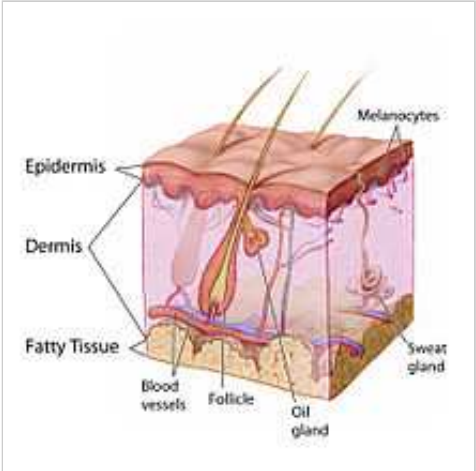

Hair follicle anatomy

Differential diagnosis

Similar conditions include rosacea, folliculitis, keratosis pilaris, perioral dermatitis, and angiofibromas among others.[12] Age is one factor that may help a physician distinguish between these disorders. Skin disorders such as perioral dermatitis and keratosis pilaris can mimic acne but tend to occur more frequently in childhood whereas rosacea tends to occur more frequently in older adults.[12] Facial redness triggered by heat or the consumption of alcohol or spicy food is suggestive of rosacea.[45] The presence of comedones can also help health professionals differentiate acne from skin disorders that are similar in appearance.[9]

Management

Many different treatments exist for acne including benzoyl peroxide, antibiotics, retinoids, antiseborrheic medications, anti-androgen medications, hormonal treatments, salicylic acid, alpha hydroxy acid, azelaic acid, nicotinamide, and keratolytic soaps.[46] They are believed to work in at least four different ways, including the following: normalizing skin cell shedding and sebum production into the pore to prevent blockage, killing *P. acnes*, anti-inflammatory effects, and hormonal manipulation.[6]

Commonly used medical treatments include topical therapies such as retinoids, antibiotics, and benzoyl peroxide and systemic therapies including oral retinoids, antibiotics, and hormonal agents.[12][47] Procedures such as light therapy and laser therapy are not considered to be first-line treatments and typically have an adjunctive role due to their high cost and limited evidence of efficacy.[47]

Medications

Benzoyl peroxide

Benzoyl peroxide cream

Benzoyl peroxide is a first-line treatment for mild and moderate acne due to its effectiveness and mild side-effects (mainly irritant dermatitis). It works against *P. acnes*, helps prevent formation of comedones, and has anti-inflammatory properties.[6] Benzoyl peroxide normally causes dryness of the skin, slight redness, and occasional peeling when side effects occur.[48] This topical does increase sensitivity to the sun as indicated on the package, so sunscreen use is often advised during the treatment to prevent sunburn. Benzoyl peroxide has been found to be nearly as effective as antibiotics with all concentrations being equally effective.[48] Unlike antibiotics, benzoyl peroxide does not appear to generate bacterial resistance.[48] Benzoyl peroxide may be paired with a topical antibiotic or retinoid such as benzoyl peroxide/clindamycin and benzoyl peroxide/adapalene, respectively.[21]

Antibiotics

Topical antibiotics are frequently used for mild to moderate severe acne.[12] Oral antibiotics are indicated for moderate to severe cases of inflammatory acne and decrease acne due to their antimicrobial activity against *P. acnes* in conjunction with anti-inflammatory properties.[6][12][48] They are believed to work both by decreasing the number of bacterial and as an anti-inflammatory.[2] With increasing resistance of *P. acnes* worldwide, they are becoming less effective.[48] Commonly used antibiotics, either applied topically or taken orally, include erythromycin (category B), clindamycin (category B), metronidazole (category B), and tetracyclines such as doxycycline and minocycline.[25] Topical erythromycin and clindamycin are considered safe to use as acne treatment during pregnancy due to negligible systemic absorption.[25] Nadifloxacin and dapsone are other topical antibiotics that may be used to treat acne in pregnant women, but have received less extensive study.[25] It is recommended that oral antibiotics be stopped and topical retinoids be used once the disease has improved.[9]

Salicylic acid

Salicylic acid (category C)[25] is a topically applied beta-hydroxy acid that possesses bacteriostatic and keratolytic properties.[49][50] Additionally, salicylic acid opens obstructed skin pores and promotes shedding of epithelial skin cells.[49] However, salicylic acid is known to be less effective than retinoid therapy.[12] Hyperpigmentation of the skin has been observed in individuals with darker skin types who use salicylic acid.[6]

Azelaic acid

Azelaic acid has been shown to be effective for mild-to-moderate acne when applied topically at a 20% concentration.[42] Application twice daily for six months is necessary, and treatment is as effective as topical benzoyl peroxide 5%, isotretinoin 0.05%, and erythromycin 2%.[51] Azelaic acid is thought to be an

effective acne treatment due to its antibacterial, anti-inflammatory, and antikeratinizing properties.[42] Azelaic acid may cause skin irritation but is otherwise very safe.[52]

Hormones

In women, acne can be improved with the use of any combined oral contraceptive.[53] The combinations that contain third or fourth generation progestins such as desogestrel, norgestimate, or drospirenone may theoretically be more beneficial.[53] Antiandrogens such as cyproterone acetate and spironolactone have also been used successfully to treat acne.[25] Hormonal therapies should not be used to treat during pregnancy or lactation as they have been associated with certain birth defects such as hypospadias and feminization of the male fetus.[25]

Topical retinoids

Topical retinoids are medications that possess anti-inflammatory properties and work by normalizing the follicle cell life cycle.[6] They are a first-line acne treatment for people with dark colored skin and are known to lead to faster improvement of post inflammatory hyperpigmentation.[21] This class includes tretinoin (category C), adapalene (category C), and tazarotene (category X).[25] Like isotretinoin, they are related to vitamin A,[6] but are administered topically and generally have much milder side effects. They can, however, cause significant irritation of the skin. The retinoids appear to influence the cell life cycle in the follicle lining. This helps prevent the hyperkeratinization of these cells that can create a blockage. Retinol is a form of vitamin A that has similar, but milder effects and is used in many over-the-counter moisturizers and other topical products. Topical retinoids often cause an initial flare-up of acne and facial flushing.

Oral retinoids

Isotretinoin is very effective for severe acne as well as moderate acne refractory to other treatments.[12] Improvement is typically seen after one to two months of use. After a single course, about 80% of people report an improvement with more than 50% reporting complete remission.[12] About 20% of people require a second course.[12] A number of adverse effects may occur including: dry skin, nose bleeds, muscle pains, increased liver enzymes, and increased lipid levels in the blood.[12] If used during pregnancy, there is a high risk of abnormalities in the baby and thus women of child bearing age are required to use effective birth control.[12] There is no clear evidence that use of oral retinoids increases the risk of psychiatric side effects such as depression and suicidality.[12]

Spironolactone

The aldosterone antagonist spironolactone is an effective treatment for acne in adult women, but is not approved by the United States' Food and Drug Administration for this purpose.[21] Spironolactone is thought to be a useful acne treatment due to its ability to block the androgen receptor at higher doses.[21] It may be used with or without an oral contraceptive.[21]

Combination therapy

Combination therapy using medications of different classes together, each with a different mechanism of action, has been demonstrated to be a more efficacious approach to acne treatment than monotherapy.[25] Frequently used combinations include the following: antibiotic + benzoyl peroxide, antibiotic + topical retinoid, or topical retinoid + benzoyl peroxide.[25]

Procedures

Comedo extraction may temporarily help those with comedones that do not improve with standard treatment.[9] A procedure for immediate relief is the injection of corticosteroids into the inflamed acne comedone.[6] There is no evidence that microdermabrasion is effective.[9]

Light therapy is a method that involves delivering intense pulses of light to the area with acne sometimes following the application of a sensitizing substance (such as aminolevulinic acid).[54] This process is thought to kill bacteria and decrease the size and activity of the glands that produce sebum.[54] As of 2012, evidence for light therapy and lasers is insufficient to recommend routine use.[9] Light therapy is expensive, and while it appears to provide short-term benefit, there is a lack of long-term outcome data or data in those with severe acne.[6][55]

Dermabrasion is an effective therapeutic procedure for reducing the appearance of superficial atrophic scars of the boxcar and rolling varieties.[19] Ice pick scars do not respond well to treatment with dermabrasion due to their depth.[19] However, the procedure is painful and has many potential side effects such as skin sensitivity to sunlight, redness, and decreased pigmentation of the skin.[19] The procedure has fallen out of favor with the introduction of laser resurfacing.[19]

Laser resurfacing can be used to reduce the scars left behind by acne.[56] Ablative fractional photothermolysis laser resurfacing was found to be more effective for reducing acne scar appearance than non-ablative fractional photothermolysis, but was associated with higher rates of postinflammatory hyperpigmentation (usually about 1 month duration), facial redness (usually for 3–14 days), and pain during the procedure.[57]

Chemical peels can also be used to reduce the appearance of acne scars.[19] Mild chemical peels include those using glycolic acid, lactic acid, salicylic acid, Jessner's solution, or a lower concentration (20%) of trichloroacetic acid. These peels only affect the epidermal layer of the skin and can be useful in the treatment of superficial acne scars as well as skin pigmentation changes from inflammatory acne.[19] Higher concentrations of trichloroacetic acid (30-40%) are considered to be medium strength peels and affect skin as deep as the papillary dermis.[19] Formulations of trichloroacetic acid concentrated to 50% or more are considered to be deep chemical peels.[19] Medium and deep strength chemical peels are more effective for deeper atrophic scars, but are more likely to cause side effects such as skin pigmentation changes, infection, or milia.[19]

Alternative medicine

Numerous natural products have been investigated for treating people with acne.[58][59] A topical application of tea tree oil has been suggested.[60] Evidence is insufficient to support their use.[61]

Prognosis

Acne usually improves around the age of 20 but may persist into adulthood.[46] Permanent physical scarring may occur.[12] There is good evidence to support the idea that acne has a negative psychological impact and worsens mood, lowers self-esteem, and is associated with a higher risk of anxiety, depression, and suicidal thoughts.[32]

Epidemiology

Globally acne affects approximately 650 million people, or about 9.4% of the population, as of 2010.[62] It affects almost 90% of people in Western societies during their teenage years and may persist into adulthood.[12] Acne after the age of 25 affects 54% of women and 40% of men.[25] Acne vulgaris has a lifetime prevalence of 85%.[25] About 20% have moderate or severe cases.[23] It is slightly more common in females than males (9.8% versus 9.0%).[62] In those over 40 years old, 1% of males and 5% of females still have problems.[12]

Rates appear to be lower in rural societies.[14] While some find it affects people of all ethnic groups,[63] it may not occur in the non-Westernized people of Papua New Guinea and Paraguay.[23]

Acne affects 40 to 50 million people in the United States (16%) and approximately 3 to 5 million in Australia (23%).[64] In the United States, acne tends to be more severe in Caucasians than people of African descent.[6]

History

- Ancient Egypt, Ancient Greece and Ancient Rome: Sulfur was used to treat acne.[65]
- 1920s: Benzoyl peroxide was used as a medication to treat acne.[66]
- 1970s: Tretinoin (original Trade Name Retin A) was found to be an effective treatment for acne.[67] This preceded the development of oral isotretinoin (sold as Accutane and Roaccutane) in 1980.[68] Also, antibiotics such as minocycline are used as treatments for acne.
- 1980s: Accutane is introduced in the United States, and later found to be a teratogen, highly likely to cause birth defects if taken during pregnancy. In the United States, more than 2,000 women became pregnant while taking the drug between 1982 and 2003, with most pregnancies ending in abortion or miscarriage. About 160 babies with birth defects were born.[69][70]

Society and culture

Cost

The social and economic costs of treating acne vulgaris are substantial. In the United States, acne vulgaris is responsible for more than 5 million doctor visits and costs over $2.5 billion each year in direct costs.[5] Similarly, acne vulgaris is responsible for 3.5 million doctor visits each year in the United Kingdom.[12]

Stigma

Misperceptions about acne's causative and aggravating factors are common and those affected by acne are often blamed for their condition.[4] Such blame can worsen the affected person's sense of self-esteem.[4] Acne vulgaris and its resultant scars have been associated with significant social difficulties that can last into adulthood.[71]

Research

A vaccine against inflammatory acne has been tested successfully in mice, but has not yet been proven to be effective in humans.[72]

In 2007, the first genome sequencing of a *P. acnes* bacteriophage (PA6) occurred which should greatly enhance the development of a potential bacteriophage therapy to treat acne and, therefore, overcome the significant problems associated with long-term antibiotic therapy and bacterial resistance.[73]

References

1. Adityan B, Kumari R, Thappa DM (May 2009). "Scoring systems in acne vulgaris". *Indian Journal of Dermatology, Venereology and Leprology* **75** (3): 323–6. doi:10.4103/0378-6323.51258 (https://dx.doi.org/10.4103%2F0378-6323.51258). PMID 19439902 (https://www.ncbi.nlm.nih.gov/pubmed/19439902).
2. Bhate, K; Williams, HC (March 2013). "Epidemiology of acne vulgaris.". *The British journal of dermatology* **168** (3): 474–85. PMID 23210645 (https://www.ncbi.nlm.nih.gov/pubmed/23210645).
3. Barnes LE, Levender MM, Fleischer AB Jr, Feldman SR (April 2012). "Quality of life measures for acne patients". *Dermatologic Clinics* **30** (2): 293–300. doi:10.1016/j.det.2011.11.001 (https://dx.doi.org/10.1016%2Fj.det.2011.11.001). PMID 22284143 (https://www.ncbi.nlm.nih.gov/pubmed/22284143).
4. Goodman, G (July 2006). "Acne and acne scarring–the case for active and early intervention" (http://www.racgp.org.au/afp/200607/8194). *Australian family physician* **35** (7): 503–4. PMID 16820822 (https://www.ncbi.nlm.nih.gov/pubmed/16820822).
5. Knutsen-Larson S, Dawson AL, Dunnick CA, Dellavalle RP (January 2012). "Acne vulgaris: pathogenesis, treatment, and needs assessment". *Dermatologic Clinics* **30** (1): 99–106. doi:10.1016/j.det.2011.09.001 (https://dx.doi.org/10.1016%2Fj.det.2011.09.001). PMID 22117871 (https://www.ncbi.nlm.nih.gov/pubmed/22117871).
6. Benner N, Sammons D (September 2013). "Overview of the treatment of acne vulgaris". *Osteopathic Family*

Physician **5** (5): 185–90. doi:10.1016/j.osfp.2013.03.003 (https://dx.doi.org/10.1016%2Fj.osfp.2013.03.003).

7. James WD (April 2005). "Acne". *New England Journal of Medicine* **352** (14): 1463–72. doi:10.1056/NEJMcp033487 (https://dx.doi.org/10.1056%2FNEJMcp033487). PMID 15814882 (https://www.ncbi.nlm.nih.gov/pubmed/15814882).
8. Mahmood SN, Bowe WP (April 2014). "Diet and acne update: carbohydrates emerge as the main culprit". *Journal of drugs in dermatology: JDD* **13** (4): 428–35. PMID 24719062 (https://www.ncbi.nlm.nih.gov/pubmed/24719062).
9. Titus S, Hodge J (October 2012). "Diagnosis and treatment of acne" (http://www.aafp.org/afp/2012/1015/p734.html). *American family physician* **86** (8): 734–40. PMID 23062156 (https://www.ncbi.nlm.nih.gov/pubmed/23062156).
10. Beylot, C; Auffret, N; Poli, F; Claudel, JP; Leccia, MT; Del Giudice, P; Dreno, B (March 2014). "Propionibacterium acnes: an update on its role in the pathogenesis of acne.". *Journal of the European Academy of Dermatology and Venereology : JEADV* **28** (3): 271–8. PMID 23905540 (https://www.ncbi.nlm.nih.gov/pubmed/23905540).
11. Taylor, Marisa; Gonzalez, Maria; Porter, Rebecca (May–June 2011). "Pathways to inflammation: acne pathophysiology". *European Journal of Dermatology* **21** (3): 323–33. doi:10.1684/ejd.2011.1357 (https://dx.doi.org/10.1684%2Fejd.2011.1357). PMID 21609898 (https://www.ncbi.nlm.nih.gov/pubmed/21609898).
12. Dawson AL, Dellavalle RP (May 2013). "Acne vulgaris". *BMJ* **346** (5): f2634. doi:10.1136/bmj.f2634 (https://dx.doi.org/10.1136%2Fbmj.f2634). PMID 23657180 (https://www.ncbi.nlm.nih.gov/pubmed/23657180).
13. Berlin, David J. Goldberg, Alexander L. *Acne and Rosacea Epidemiology, Diagnosis and Treatment.* (http://books.google.ca/books?id=ZSjauawI1FsC&pg=PA8&dq) London: Manson Pub. p. 8. ISBN 9781840766165.
14. Spencer EH, Ferdowsian, Barnard ND (April 2009). "Diet and acne: a review of the evidence.". *International Journal of Dermatology* **48** (4): 339–47. doi:10.1111/j.1365-4632.2009.04002.x (https://dx.doi.org/10.1111%2Fj.1365-4632.2009.04002.x). PMID 19335417 (https://www.ncbi.nlm.nih.gov/pubmed/19335417).
15. Hay, RJ; Johns, NE; Williams, HC; Bolliger, IW; Dellavalle, RP; Margolis, DJ; Marks, R; Naldi, L; Weinstock, MA; Wulf, SK; Michaud, C; J L Murray, C; Naghavi, M (October 2013). "The Global Burden of Skin Disease in 2010: An Analysis of the Prevalence and Impact of Skin Conditions". *The Journal of investigative dermatology* **134** (6): 1527–34. doi:10.1038/jid.2013.446 (https://dx.doi.org/10.1038%2Fjid.2013.446). PMID 24166134 (https://www.ncbi.nlm.nih.gov/pubmed/24166134).
16. Admani S, Barrio VR (November 2013). "Evaluation and treatment of acne from infancy to preadolescence". *Dermatologic therapy* **26** (6): 462–6. doi:10.1111/dth.12108 (https://dx.doi.org/10.1111%2Fdth.12108). PMID 24552409 (https://www.ncbi.nlm.nih.gov/pubmed/24552409).
17. Zhao YE, Hu L, Wu LP, Ma JX (March 2012). "A meta-analysis of association between acne vulgaris and Demodex infestation" (https://www.ncbi.nlm.nih.gov/pmc/articles/PMC3296070). *Journal of Zhejiang University. Science. B* **13** (3): 192–202. doi:10.1631/jzus.B1100285 (https://dx.doi.org/10.1631%2Fjzus.B1100285). PMC 3296070 (https://www.ncbi.nlm.nih.gov/pmc/articles/PMC3296070). PMID 22374611 (https://www.ncbi.nlm.nih.gov/pubmed/22374611).
18. Thiboutot, Diane M.; Strauss, John S. (2003). "Diseases of the sebaceous glands". In Burns, Tony; Breathnach,

Stephen; Cox, Neil; Griffiths, Christopher. *Fitzpatrick's dermatology in general medicine* (6th ed.). New York: McGraw-Hill. pp. 672–87. ISBN 0-07-138076-0.

19. Levy, LL; Zeichner, JA (October 2012). "Management of acne scarring, part II: a comparative review of non-laser-based, minimally invasive approaches". *Am J Clin Dermatol* **13** (5): 331–40. doi:10.2165/11631410-000000000-00000 (https://dx.doi.org/10.2165%2F11631410-000000000-00000). PMID 22849351 (https://www.ncbi.nlm.nih.gov/pubmed/22849351).
20. Sobanko, JF; Alster, TS (October 2012). "Management of acne scarring, part I: a comparative review of laser surgical approaches". *Am J Clin Dermatol* **13** (5): 319–30. doi:10.2165/11598910-000000000-00000 (https://dx.doi.org/10.2165%2F11598910-000000000-00000). PMID 22612738 (https://www.ncbi.nlm.nih.gov/pubmed/22612738).
21. Yin NC, McMichael AJ (February 2014). "Acne in patients with skin of color: practical management". *American Journal of Clinical Dermatology* **15** (1): 7–16. doi:10.1007/s40257-013-0049-1 (https://dx.doi.org/10.1007%2Fs40257-013-0049-1). PMID 24190453 (https://www.ncbi.nlm.nih.gov/pubmed/24190453).
22. Callender, VD; St Surin-Lord, S; Davis, EC; Maclin, M (April 2011). "Postinflammatory hyperpigmentation: etiologic and therapeutic considerations". *Am J Clin Dermatol* **12** (2): 87–99. doi:10.2165/11536930-000000000-00000 (https://dx.doi.org/10.2165%2F11536930-000000000-00000). PMID 21348540 (https://www.ncbi.nlm.nih.gov/pubmed/21348540).
23. Bhate K, Williams HC (March 2013). "Epidemiology of acne vulgaris.". *The British journal of dermatology* **168** (3): 474–85. doi:10.1111/bjd.12149 (https://dx.doi.org/10.1111%2Fbjd.12149). PMID 23210645 (https://www.ncbi.nlm.nih.gov/pubmed/23210645).
24. "Frequently Asked Questions: Acne" (http://www.womenshealth.gov/faq/acne.cfm). U.S. Department of Health and Human Services, Office of Public Health and Science, Office on Women's Health. 16 July 2009. Retrieved 2009-07-30.
25. Kong YL, Tey HL (June 2013). "Treatment of acne vulgaris during pregnancy and lactation". *Drugs* **73** (8): 779–87. doi:10.1007/s40265-013-0060-0 (https://dx.doi.org/10.1007%2Fs40265-013-0060-0). PMID 23657872 (https://www.ncbi.nlm.nih.gov/pubmed/23657872).
26. Hoeger, Peter H.; Alan D. Irvine; Albert C. Yan (2011). *Chapter 79 Acne Harper's Textbook of Pediatric Dermatology* (3rd ed.). New Jersey: Wiley-Blackwell. ISBN 978-1-44-434536-0.
27. Melnik, Bodo; Jansen, Thomas; Grabbe, Stephan (2007). "Abuse of anabolic-androgenic steroids and bodybuilding acne: An underestimated health problem". *JDDG* **5** (2): 110–17. doi:10.1111/j.1610-0387.2007.06176.x (https://dx.doi.org/10.1111%2Fj.1610-0387.2007.06176.x). PMID 17274777 (https://www.ncbi.nlm.nih.gov/pubmed/17274777).
28. Holzmann R, Shakery K (November 2013). "Postadolescent acne in females". *Skin pharmacology and physiology* **27** (Supplement 1): 3–8. doi:10.1159/000354887 (https://dx.doi.org/10.1159%2F000354887). PMID 24280643 (https://www.ncbi.nlm.nih.gov/pubmed/24280643).
29. Housman E, Reynolds RV (November 2014). "Polycystic ovary syndrome: A review for dermatologists: Part I. Diagnosis and manifestations". *Journal of the American Academy of Dermatology* **71** (5): 847. doi:10.1016/j.jaad.2014.05.007 (https://dx.doi.org/10.1016%2Fj.jaad.2014.05.007). PMID 25437977 (https://www.ncbi.nlm.nih.gov/pubmed/25437977).
30. Bek-Thomsen, M.; Lomholt, H. B.; Kilian, M. (2008). "Acne is Not Associated with Yet-Uncultured Bacteria" (https://www.ncbi.nlm.nih.gov/pmc/articles/PMC2566126). *Journal of Clinical Microbiology* **46** (10): 3355–60

(https://www.ncbi.nlm.nih.gov/pmc/articles/PMC2566126). *Journal of Clinical Microbiology* **46** (10): 3355–60. doi:10.1128/JCM.00799-08 (https://dx.doi.org/10.1128%2FJCM.00799-08). PMC 2566126 (https://www.ncbi.nlm.nih.gov/pmc/articles/PMC2566126). PMID 18716234 (https://www.ncbi.nlm.nih.gov/pubmed/18716234).

31. Lomholt, Hans B.; Kilian, Mogens (2010). Bereswill, Stefan, ed. "Population Genetic Analysis of Propionibacterium acnes Identifies a Subpopulation and Epidemic Clones Associated with Acne" (https://www.ncbi.nlm.nih.gov/pmc/articles/PMC2924382). *PLoS ONE* **5** (8): e12277. doi:10.1371/journal.pone.0012277 (https://dx.doi.org/10.1371%2Fjournal.pone.0012277). PMC 2924382 (https://www.ncbi.nlm.nih.gov/pmc/articles/PMC2924382). PMID 20808860 (https://www.ncbi.nlm.nih.gov/pubmed/20808860).
32. Bhate K, Williams HC (April 2014). "What's new in acne? An analysis of systematic reviews published in 2011-2012". *Clinical and experimental dermatology* **39** (3): 273–7. doi:10.1111/ced.12270 (https://dx.doi.org/10.1111%2Fced.12270). PMID 24635060 (https://www.ncbi.nlm.nih.gov/pubmed/24635060).
33. Davidovici, Batya B.; Wolf, Ronni (2010). "The role of diet in acne: Facts and controversies". *Clinics in Dermatology* **28** (1): 12–6. doi:10.1016/j.clindermatol.2009.03.010 (https://dx.doi.org/10.1016%2Fj.clindermatol.2009.03.010). PMID 20082944 (https://www.ncbi.nlm.nih.gov/pubmed/20082944).
34. Melnik, BC; John, SM; Plewig, G (November 2013). "Acne: risk indicator for increased body mass index and insulin resistance" (http://www.medicaljournals.se/acta/content/?doi=10.2340/00015555-1677&html=1). *Acta dermato-venereologica* **93** (6): 644–9. doi:10.2340/00015555-1677 (https://dx.doi.org/10.2340%2F00015555-1677). PMID 23975508 (https://www.ncbi.nlm.nih.gov/pubmed/23975508).
35. Ferdowsian HR, Levin S (March 2010). "Does diet really affect acne?" (http://www.skintherapyletter.com/2010/15.3/1.html). *Skin therapy letter* **15** (3): 1–2, 5. PMID 20361171 (https://www.ncbi.nlm.nih.gov/pubmed/20361171).
36. Melnik, Bodo C. (2011). "Evidence for Acne-Promoting Effects of Milk and Other Insulinotropic Dairy Products". *Milk and Milk Products in Human Nutrition*. Nestlé Nutrition Institute Workshop Series: Pediatric Program **67**. p. 131. doi:10.1159/000325580 (https://dx.doi.org/10.1159%2F000325580). ISBN 978-3-8055-9587-2.
37. Melnik, Bodo C.; Schmitz, Gerd (2009). "Role of insulin, insulin-like growth factor-1, hyperglycaemic food and milk consumption in the pathogenesis of acne vulgaris". *Experimental Dermatology* **18** (10): 833–41. doi:10.1111/j.1600-0625.2009.00924.x (https://dx.doi.org/10.1111%2Fj.1600-0625.2009.00924.x). PMID 19709092 (https://www.ncbi.nlm.nih.gov/pubmed/19709092).
38. Cordain L (June 2005). "Implications for the Role of Diet in Acne". *Seminars in Cutaneous Medicine and Surgery* **24** (2): 84–91. doi:10.1016/j.sder.2005.04.002 (https://dx.doi.org/10.1016%2Fj.sder.2005.04.002). PMID 16092796 (https://www.ncbi.nlm.nih.gov/pubmed/16092796).
39. Brescoll, J; Daveluy, S (February 2015). "A review of vitamin B12 in dermatology.". *American journal of clinical dermatology* **16** (1): 27–33. doi:10.1007/s40257-014-0107-3 (https://dx.doi.org/10.1007%2Fs40257-014-0107-3). PMID 25559140 (https://www.ncbi.nlm.nih.gov/pubmed/25559140).
40. Chiu A, Chon SY, Kimball AB (July 2003). "The Response of Skin Disease to Stress". *Archives of Dermatology* **139** (7): 897–900. doi:10.1001/archderm.139.7.897 (https://dx.doi.org/10.1001%2Farchderm.139.7.897). PMID 12873885 (https://www.ncbi.nlm.nih.gov/pubmed/12873885).
41. "Questions and Answers about Acne" (http://www.niams.nih.gov/Health_Info/Acne/default.asp).

http://www.niams.nih.gov/. May 2013. Retrieved 30 January 2015.

42. Sieber, MA; Hegel, JK (November 2013). "Azelaic acid: Properties and mode of action". *Skin Pharmacol Physiol* **27** (Supplement 1): 9–17. doi:10.1159/000354888 (https://dx.doi.org/10.1159%2F000354888). PMID 24280644 (https://www.ncbi.nlm.nih.gov/pubmed/24280644).
43. Simpson, Nicholas B.; Cunliffe, William J. (2004). "Disorders of the sebaceous glands". In Burns, Tony; Breathnach, Stephen; Cox, Neil; Griffiths, Christopher. *Rook's textbook of dermatology* (7th ed.). Malden, Mass.: Blackwell Science. pp. 43.1–75. ISBN 0-632-06429-3.
44. Leeds, Cook's and Pillsbury scales obtained from here (http://www.clinicalevidence.com/ceweb/conditions/skd/1714/1714_background.jsp#outcomes)
45. Archer CB, Cohen SN, Baron SE; British Association of Dermatologists and Royal College of General Practitioners (May 2012). "Guidance on the diagnosis and clinical management of acne". *Clinical and experimental dermatology* **37** (Supplement 1): 1–6. doi:10.1111/j.1365-2230.2012.04335.x (https://dx.doi.org/10.1111%2Fj.1365-2230.2012.04335.x). PMID 22486762 (https://www.ncbi.nlm.nih.gov/pubmed/22486762).
46. Ramos-e-Silva M, Carneiro SC (March 2009). "Acne vulgaris: Review and guidelines". *Dermatology nursing/Dermatology Nurses' Association* **21** (2): 63–8; quiz 69. PMID 19507372 (https://www.ncbi.nlm.nih.gov/pubmed/19507372).
47. Simonart T (December 2012). "Newer approaches to the treatment of acne vulgaris". *America Journal of Clinical Dermatology* **13** (6): 357–64. doi:10.2165/11632500-000000000-00000 (https://dx.doi.org/10.2165%2F11632500-000000000-00000). PMID 22920095 (https://www.ncbi.nlm.nih.gov/pubmed/22920095).
48. Sagransky, Matt; Yentzer, Brad A; Feldman, Steven R (2009). "Benzoyl peroxide: A review of its current use in the treatment of acne vulgaris". *Expert Opinion on Pharmacotherapy* **10** (15): 2555–62. doi:10.1517/14656560903277228 (https://dx.doi.org/10.1517%2F14656560903277228). PMID 19761357 (https://www.ncbi.nlm.nih.gov/pubmed/19761357).
49. Madan RK, Levitt J (April 2014). "A review of toxicity from topical salicylic acid preparations". *Journal of the American Academy of Dermatology* **70** (4): 788–92. doi:10.1016/j.jaad.2013.12.005 (https://dx.doi.org/10.1016%2Fj.jaad.2013.12.005). PMID 24472429 (https://www.ncbi.nlm.nih.gov/pubmed/24472429).
50. Well D (October 2013). "Acne vulgaris: A review of causes and treatment options". *The Nurse practitioner* **38** (10): 22–31. doi:10.1097/01.NPR.0000434089.88606.70 (https://dx.doi.org/10.1097%2F01.NPR.0000434089.88606.70). PMID 24048347 (https://www.ncbi.nlm.nih.gov/pubmed/24048347).
51. Morelli, Vincent; Calmet, Erick; Jhingade, Varalakshmi (2010). "Alternative Therapies for Common Dermatologic Disorders, Part 2". *Primary Care: Clinics in Office Practice* **37** (2): 285–96. doi:10.1016/j.pop.2010.02.005 (https://dx.doi.org/10.1016%2Fj.pop.2010.02.005). PMID 20493337 (https://www.ncbi.nlm.nih.gov/pubmed/20493337).
52. "Azelaic Acid Topical" (http://www.nlm.nih.gov/medlineplus/druginfo/meds/a603020.html). National Institutes Of Health. Retrieved 2013-09-09.
53. Arowojolu, Ayodele O; Gallo, Maria F; Lopez, Laureen M; Grimes, David A (2012). Arowojolu, Ayodele O, ed. "Combined oral contraceptive pills for treatment of acne". *Cochrane Database of Systematic Reviews* **7**: CD004425. doi:10.1002/14651858.CD004425.pub6 (https://dx.doi.org/10.1002%2F14651858.CD004425.pub6). PMID 22786490 (https://www.ncbi.nlm.nih.gov/pubmed/22786490).

54. Pugashetti, R; Shinkai, K (July 2013). "Treatment of acne vulgaris in pregnant patients". *Dermatol Ther* **26** (4): 302–11. doi:10.1111/dth.12077 (https://dx.doi.org/10.1111%2Fdth.12077). PMID 23914887 (https://www.ncbi.nlm.nih.gov/pubmed/23914887).
55. Hamilton, F.L.; Car, J.; Lyons, C.; Car, M.; Layton, A.; Majeed, A. (2009). "Laser and other light therapies for the treatment of acne vulgaris: Systematic review". *British Journal of Dermatology* **160** (6): 1273–85. doi:10.1111/j.1365-2133.2009.09047.x (https://dx.doi.org/10.1111%2Fj.1365-2133.2009.09047.x). PMID 19239470 (https://www.ncbi.nlm.nih.gov/pubmed/19239470).
56. Chapas, Anne M.; Brightman, Lori; Sukal, Sean; Hale, Elizabeth; Daniel, David; Bernstein, Leonard J.; Geronemus, Roy G. (2008). "Successful treatment of acneiform scarring with CO2 ablative fractional resurfacing". *Lasers in Surgery and Medicine* **40** (6): 381–6. doi:10.1002/lsm.20659 (https://dx.doi.org/10.1002%2Flsm.20659). PMID 18649382 (https://www.ncbi.nlm.nih.gov/pubmed/18649382).
57. Ong, MW; Bashir, SJ (June 2012). "Fractional laser resurfacing for acne scars: a review". *Br J Dermatol* **166** (6): 1160–9. doi:10.1111/j.1365-2133.2012.10870.x (https://dx.doi.org/10.1111%2Fj.1365-2133.2012.10870.x). PMID 22296284 (https://www.ncbi.nlm.nih.gov/pubmed/22296284).
58. Cao, Huijuan; Yang, Guoyan; Wang, Yuyi; Liu, Jian Ping; Smith, Caroline A; Luo, Hui; Liu, Yueming; Liu, Jian Ping (2015). "Complementary therapies for acne vulgaris". doi:10.1002/14651858.CD009436.pub2 (https://dx.doi.org/10.1002%2F14651858.CD009436.pub2).
59. Yarnell, Eric; Abascal, Kathy (2006). "Herbal Medicine for Acne Vulgaris". *Alternative and Complementary Therapies* **12** (6): 303–9. doi:10.1089/act.2006.12.303 (https://dx.doi.org/10.1089%2Fact.2006.12.303).
60. Pazyar, Nader; Yaghoobi, Reza; Bagherani, Nooshin; Kazerouni, Afshin (2013). "A review of applications of tea tree oil in dermatology". *International Journal of Dermatology* **52** (7): 784–90. doi:10.1111/j.1365-4632.2012.05654.x (https://dx.doi.org/10.1111%2Fj.1365-4632.2012.05654.x). PMID 22998411 (https://www.ncbi.nlm.nih.gov/pubmed/22998411).
61. Costa, CS; Bagatin, E (2013). "Evidence on acne therapy" (http://www.scielo.br/scielo.php?script=sci_arttext&pid=S1516-31802013000300193&lng=en&nrm=iso&tlng=en). *Sao Paulo medical journal = Revista paulista de medicina* **131** (3): 193–7. PMID 23903269 (https://www.ncbi.nlm.nih.gov/pubmed/23903269).
62. Vos, Theo; Flaxman (2012). "Years lived with disability (YLDs) for 1160 sequelae of 289 diseases and injuries 1990–2010: A systematic analysis for the Global Burden of Disease Study 2010". *The Lancet* **380** (9859): 2163–96. doi:10.1016/S0140-6736(12)61729-2 (https://dx.doi.org/10.1016%2FS0140-6736%2812%2961729-2). PMID 23245607 (https://www.ncbi.nlm.nih.gov/pubmed/23245607).
63. Shah, Sejal K.; Alexis, Andrew F. (2010). "Acne in skin of color: Practical approaches to treatment". *Journal of Dermatological Treatment* **21** (3): 206–11. doi:10.3109/09546630903401496 (https://dx.doi.org/10.3109%2F09546630903401496). PMID 20132053 (https://www.ncbi.nlm.nih.gov/pubmed/20132053).
64. White GM (August 1998). "Recent findings in the epidemiologic evidence, classification, and subtypes of acne vulgaris". *Journal of the American Academy of Dermatology* **39** (2): S34–37. doi:10.1016/S0190-9622(98)70442-6 (https://dx.doi.org/10.1016%2FS0190-9622%2898%2970442-6). PMID 9703121 (https://www.ncbi.nlm.nih.gov/pubmed/9703121).
65. Keri J, Shiman M (2009). "An update on the management of acne vulgaris" (http://www.ncbi.nlm.nih.gov/pmc/articles/PMC3047935/). *Clin Cosmet Investig Dermatol* **17** (2): 105–10. PMC 3047935 (https://www.ncbi.nlm.nih.gov/pmc/articles/PMC3047935). PMID 21436973

PMC 3047955 (https://www.ncbi.nlm.nih.gov/pmc/articles/PMC3047955). PMID 21436973 (https://www.ncbi.nlm.nih.gov/pubmed/21436973).

66. Myra Michelle Eby, Michelle Eby Myra. *Return to Beautiful Skin*. Basic Health Publications. p. 275.
67. "Tretinoin (retinoic acid) in acne". *The Medical letter on drugs and therapeutics* **15** (1): 3. 1973. PMID 4265099 (https://www.ncbi.nlm.nih.gov/pubmed/4265099).
68. Jones, H (1980). "13-Cis Retinoic Acid and Acne". *The Lancet* **316** (8203): 1048–9. doi:10.1016/S0140-6736(80)92273-4 (https://dx.doi.org/10.1016%2FS0140-6736%2880%2992273-4). PMID 6107678 (https://www.ncbi.nlm.nih.gov/pubmed/6107678).
69. Bérard, Anick; Azoulay, Laurent; Koren, Gideon; Blais, Lucie; Perreault, Sylvie; Oraichi, Driss (2007). "Isotretinoin, pregnancies, abortions and birth defects: A population-based perspective" (https://www.ncbi.nlm.nih.gov/pmc/articles/PMC1859978). *British Journal of Clinical Pharmacology* **63** (2): 196–205. doi:10.1111/j.1365-2125.2006.02837.x (https://dx.doi.org/10.1111%2Fj.1365-2125.2006.02837.x). PMC 1859978 (https://www.ncbi.nlm.nih.gov/pmc/articles/PMC1859978). PMID 17214828 (https://www.ncbi.nlm.nih.gov/pubmed/17214828).
70. Holmes, SC; Bankowska, U; MacKie, RM (1998). "The prescription of isotretinoin to women: Is every precaution taken?". *British Journal of Dermatology* **138** (3): 450–55. doi:10.1046/j.1365-2133.1998.02123.x (https://dx.doi.org/10.1046%2Fj.1365-2133.1998.02123.x). PMID 9580798 (https://www.ncbi.nlm.nih.gov/pubmed/9580798).
71. Brown MM, Chamlin SL, Smidt AC (April 2013). "Quality of life in pediatric dermatology". *Dermatologic Clinics* **31** (2): 211–21. doi:10.1016/j.det.2012.12.010 (https://dx.doi.org/10.1016%2Fj.det.2012.12.010). PMID 23557650 (https://www.ncbi.nlm.nih.gov/pubmed/23557650).
72. Kim, Jenny (2008). "Acne Vaccines: Therapeutic Option for the Treatment of Acne Vulgaris?". *Journal of Investigative Dermatology* **128** (10): 2353–54. doi:10.1038/jid.2008.221 (https://dx.doi.org/10.1038%2Fjid.2008.221). PMID 18787542 (https://www.ncbi.nlm.nih.gov/pubmed/18787542).
73. Farrar, M. D.; Howson, K. M.; Bojar, R. A.; West, D.; Towler, J. C.; Parry, J.; Pelton, K.; Holland, K. T. (2007). "Genome Sequence and Analysis of a Propionibacterium acnes Bacteriophage" (https://www.ncbi.nlm.nih.gov/pmc/articles/PMC1913406). *Journal of Bacteriology* **189** (11): 4161–67. doi:10.1128/JB.00106-07 (https://dx.doi.org/10.1128%2FJB.00106-07). PMC 1913406 (https://www.ncbi.nlm.nih.gov/pmc/articles/PMC1913406). PMID 17400737 (https://www.ncbi.nlm.nih.gov/pubmed/17400737).

External links

- Questions and Answers about Acne (http://niams.nih.gov/Health_Info/Acne/default.asp) - US National Institute of Arthritis and Musculoskeletal and Skin Diseases

Media related to Acne at Wikimedia Commons

Retrieved from "http://en.wikipedia.org/w/index.php?title=Acne_vulgaris&oldid=651442731"

Categories: Acneiform eruptions

- This page was last modified on 15 March 2015, at 06:04.
- Text is available under the Creative Commons Attribution-ShareAlike License; additional terms may apply. By using this site, you agree to the Terms of Use and Privacy Policy. Wikipedia® is a registered trademark of the Wikimedia Foundation, Inc., a non-profit organization.

Exhibit 6

PROCEDURES
thermage / thermalift
laser skin resurfacing
IPL Photorejuvenation
restylane / collagen
botox
laser hair removal
MicroLaserPeel
blu-u / pdt photodynamic
spider vein sclerotherapy
chemical peel

ABOUT
about Dr. Day
patient testimonials
about dermatology
dermatologist plus
f. a. q.

FACILITY
our facility
our location
pricing

Dr. Joanna Day
Dermatology & Laser Centre
Suite 103 - 2419 Bellevue Ave
West Vancouver, BC, V7V 4T4
Canada

Phone: 604-925-9798
Toll free: 1-866-933-7329
contact@drjoannaday.com

PHOTODAMAGED SKIN

Photodamaged or sun damaged skin is something few escape. Photodamage occurs with exposure to sunlight (UVA or UVB) whether or not we intentionally suntan. Twenty five percent of our lifetime exposure occurs before the end of our teenage years. Photodamage to skin manifests in a variety of ways including:

- advanced aging or wrinkling
- uneven or "pebbly" skin
- irregular pigmentation
- small blood vessels or red markings (telangiectasias)
- rough or scaly patches (actinic keratoses)
- freckles (ephilides)
- "liver spots" and "age spots" (lentigines)
- thinned or fragile skin
- pre skin cancers
- skin cancer (basal cell carcinoma, squamous cell carcinoma, malignant melanoma).

For the most part these changes occur most frequently on areas of chronic exposure including the face, ears, neck, backs of the hands, chest, arms and legs. Buttocks or upper inner arms are often preserved and pristine emphasizing the difference between chronological aging and photoaging.

As the manifestations of photodamage are numerous, the importance of being examined by a qualified dermatologist is paramount. Prior to any treatment, an examination by Dr Joanna Day will ensure your safety. As a medical dermatologist Dr Day uses the newest technologies available to provide rejuvenation to photo-damaged skin.

We offer several rejuvenating, preventative and/or therapeutic procedures at our clinic including MicroLaserPeel, IPL Photorejuventaion and photodynamic therapy (PDT) including ALA/IPL, ALA/Blu-U and ALA/IPL/Blu-U. All options will be discussed and an appropriate treatment program may be suggested depending upon your skin's requirements following your consultation and examination by Dr Day.

BEFORE AFTER

forehead lines
frown lines
general wrinkles
lip enhancement
perioral lip wrinkles
face & neck jowls
acne
acne scars
crows feet
deep smile folds
brow
unwanted hair
downturned mouth
marionette folds
preskin cancer
photodamaged skin
pores tone texture
veins & rosacea
pigmentation

Site Map

Intended for Canadian Residents.

© 1999-2015 Dr Joanna Day Inc. All rights reserved. No parts of this web site may be used, borrowed or copied without express written permission by Dr Joanna Day, Inc. Thank you for visitng. By using this service, you accept the terms of our Visitor Agreement. Please read it. The material on drjoannaday.com is for informational purposes only and is not a substitute for medical advice or treatment for any medical conditions.

Exhibit 7

IN THIS ARTICLE

SIGNS & SYMPTOMS
CAUSES & TRIGGERS
CONTRIBUTING FACTORS
SOLUTIONS

Hyperpigmentation: what it is and how to recognise it

Hyperpigmentation can cause significant distress as the dark spots tend to appear on the face, hands, and other highly visible body parts that have been exposed to the sun, and can be difficult to hide.

SIGNS & SYMPTOMS

WHAT IS HYPERPIGMENTATION? AND WHY DOES IT OCCUR?

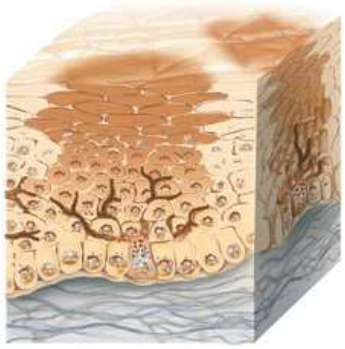

Hyperpigmentation results in flat, darkened patches of skin that can vary in size and colour.

Hyperpigmentation occurs when melanin is overproduced in certain spots on the skin.

> Hyperpigmentation results in flat, darkened patches of skin that are light brown to black in colour, and can vary in size and shape.

There are many types of hyperpigmentation, but the following are the most common:

Pigment spots such as **age spots** are caused by sun exposure. For this reason, they appear mainly on body parts that are frequently exposed, such as

the face, hands and arms. They tend to be small, darkened patches of skin.

Melasma or **chloasma** → is often referred to as "the mask of pregnancy", as it affects 90% of pregnant women. It occurs as a result of hormonal influences such as pregnancy and birth control pills, and causes dark and irregularly shaped areas on the face or arms that can be quite large.

Freckles are caused by sun exposure, and commonly appear on the face.

Post-inflammatory hyperpigmentation → occurs when a skin injury or trauma heals and leaves a flat area of discolouration behind. It's commonly found among acne sufferers, and can also be caused by cosmetic procedures such as dermabrasion, laser treatment and chemical peels.

There are other factors that can cause patches of skin to become darker – such as scarring, birthmarks, solar or actinic keratoses and skin cancers – but these aren't considered to be forms of hyperpigmentation.

See your dermatologist or pharmacist if you are concerned about any of your dark spots, or if they are new, start to bleed, itch, or change in size or colour.

CAUSES & TRIGGERS

WHAT MAKES HYPERPIGMENTATION AND DARK SPOTS APPEAR?

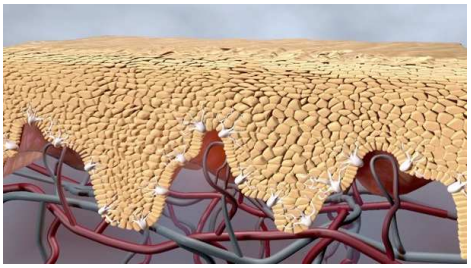

0:00 / 0:00

Hyperpigmentation is caused by an overproduction of melanin – the pigment that gives our skin, hair and eyes its natural colour – in patches of the skin. This overproduction is triggered by a variety of factors, but the main ones can be linked back to sun exposure, genetic factors, age, hormonal influences, and skin injuries or inflammation. Learn more about the causes of hyperpigmentation →.

CONTRIBUTING FACTORS

THE MAIN CONTRIBUTING FACTORS

Sunlight triggers melanin production, making it the number one cause of hyperpigmentation.

Sun exposure is the number one cause of hyperpigmentation, as it's sunlight that triggers the production of melanin in the first place. Melanin acts as your skin's natural sunscreen by protecting you from harmful UV rays, which is why people tan in the sun. But excessive sun exposure can disrupt this process, leading to hyperpigmentation.

Once dark spots have developed, sun exposure can also exacerbate dark spots by making freckles, age spots →, melasma → and post-inflammatory hyperpigmentation → spots even darker.

Limiting the time you spend in the sun, wearing protective clothing, and using a broad-spectrum sunscreen with a high SPF can help reduce your risk of developing hyperpigmentation, and stop existing dark spots from getting worse.

Hyperpigmentation on the upper lip can occur due to hormonal changes.

Hormonal influences are the main cause of a particular kind of hyperpigmentation known as melasma or chloasma. It's particularly common among women, as it's thought to occur when the female sex hormones oestrogen and progesterone stimulate the overproduction of melanin when skin is exposed to the sun.

Melasma is primarily due to female hormones. It affects so many pregnant women that it is also known as "the mask of pregnancy". It's more prevalent among people with darker skin.

Hyperpigmentation is also symptomatic of certain **illnesses**, such as some autoimmune and gastrointestinal diseases, metabolic disorders and vitamin deficiencies. Hyperpigmentation is also a side effect of certain hormone treatments, chemotherapy drugs, antibiotics, antimalarials, anti-seizure drugs, and other **medications**.

Melasma – a form of hormone-induced hyperpigmentation – affects around 90% of pregnant women.

Photocontact dermatitis caused by **henna dyes or tattooing** can result in residual hyperpigmentation.

Certain **jobs or occupations** are also linked to hyperpigmentation due to their associated risk of exposure to sun or chemicals. People known to be at added risk include gardeners, pitch or tar workers, and those who work in perfumeries or bakeries.

As its name suggests, post-inflammatory hyperpigmentation → occurs following a skin injury or inflammation, such as a cut, burn, chemical exposure, acne →, eczema or Psoriasis →. It occurs when the skin is left darkened and discoloured after the wound has healed.

Certain illnesses and medications are known to cause hyperpigmentation.

SOLUTIONS

WHAT CAN YOU DO ABOUT HYPERPIGMENTATION?

Dermatological treatments – anti-pigmentation procedures

A chemical peel is one way to remove hyperpigmentation and reveal new and evenly pigmented skin.

Chemical peels involve applying an acidic solution to the face, hands or feet to remove the surface layers of the skin. These chemicals cause the skin to blister and eventually peel off, revealing new and evenly pigmented skin beneath.

Laser therapies have much the same effect, but tend to be more precise, as the dermatologist has more control over the intensity of the treatment. They involve 'zapping' the affected areas with high-energy light. The mildest treatments work just on the skin's epidermis (surface layer), while more intense treatments can penetrate the deepest layers of the skin.

Laser treatments have a similar effect to chemical peels, but the treatment can be applied more precisely.

These dermatological treatments can be very effective against hyperpigmentation but they are expensive and relatively invasive. And because they can irritate, inflame or even burn skin, they can actually cause post-inflammatory hyperpigmentation →, especially in people with darker skin.

Other options

In recent years, a number of skincare products that claim to reduce hyperpigmentation have emerged. Most rely on one of the following active ingredients to decrease melanin production and reduce the appearance of dark spots.

Until recently, **hydroquinone or hydrochinone** was the most powerful active ingredient for treating hyperpigmentation. It's still available in some over-the-counter remedies in the US, but only in low concentrations of 2% or less. Hydroquinone can also cause post-inflammatory hyperpigmentation, as it's a skin irritant.

Arbutin is a natural source of hydroquinone, and is one of the key ingredients used in skin whitening products in Asia. It's not as strong or effective as industrially produced hydroquinone, but there are also safety concerns.

Kojic acid is a by-product of the fermentation process involved in producing the Japanese rice wine, sake. It is a fairly weak inhibitor of melanin production. It has been banned in many countries.

Vitamin C derivatives have been shown to be relatively effective against hyperpigmentation. They're often used in conjunction with other active ingredients.

Retinoid acid derivatives have also been shown to be relatively effective as a hyperpigmentation treatment. But they can both irritate skin and make it more sensitive to the sun, which can of course worsen hyperpigmentation. Concerns about the links between retinoids and birth defects also mean they're not recommended for pregnant or breastfeeding women.

Azelaic acid has also been shown to indirectly affect melanin production and reduce hyperpigmentation. It has little to no effect on freckles and age spots, and can irritate and inflame skin.

A number of topical creams for hyperpigmentation have emerged in recent years.

Some skincare products for hyperpigmentation can be used on both the face and body.

> Tests have shown B-Resorcinol to be highly effective at reducing melanin production.

B-Resorcinol or butyl resorcinol is the main active ingredient in the Eucerin Even Brighter Clinical range

B-Resorcinol, the main active ingredient in EVEN BRIGHTER, has been shown to reduce the appearance of dark spots.

Using a broad-spectrum sunscreen every day can help prevent hyperpigmentation.

→. It causes little to no skin irritation and is effective against the major kinds of hyperpigmentation, like melasma and age spots.

B-Resorcinol has been clinically proven to start visibly reducing dark spots in four weeks. Regular use can produce even better results. Learn more about B-resorcinol →.

There have also been claims that other treatments – such as jojoba oil, lemon juice, or following a sugar-free diet – can also be effective against hyperpigmentation. However, there's no scientific evidence to support these claims.

Whatever option you choose, make sure you use a **broad-spectrum sunscreen** every day to prevent further hyperpigmentation. The Even Brighter Clinical Day Cream → contains a SPF, as well as B-Resorcinol to reduce existing dark spots.

– HYPERPIGMENTATION –

EVEN BRIGHTER Concentrate

– HYPERPIGMENTATION –

EVEN BRIGHTER Day Cream

– HYPERPIGMENTATION –

EVEN BRIGHTER Night Cream

COPYRIGHT © BEIERSDORF 2015

Exhibit 8

What Is Skin Rejuvenation And How It Can Be Achieved?

By Nicholas Hurd | Submitted On May 26, 2008

Most anti aging products lay claim to skin rejuvenation properties however, what does this really mean? What Is Skin Rejuvenation and How It Can Be Achieved? Having an understanding of this process might assist you to select the correct procedure your yourself.

Definition of Skin Rejuvenation

The skin rejuvenation process is defined as a process that takes place to attempt the reversal of visible signs of ageing. Skin rejuvenation processes have the ability to diminish wrinkles and lines as well as firm loose and sagging areas of the skin leaving the skin with a younger appearance. There are some surgical and medical procedures that can enable this.

The Face Lift

This method of skin rejuvenation can be carried out both surgically and non-surgically and is an efficient way of eliminating wrinkled or sagging skin as well as firm and tone.

Surgical face lifts are invasive and entails an incision in the hairline, traveling right around the upper part of your head. The surgeon will then peel the skin back to repair and rebuild underlying damaged tissue, he then replaces the skin, pulling it back while trimming any excess, it is then reattached to its original position.

The non-surgical face lift repairs facial tissue with the use of extreme heat through radio frequencies, laser surgery or electrical currents. The laser procedure creates a resurfacing of the skin by burning off old cells. Heat and electrical treatment works collagen groups, strengthening and building them and thereby promoting skin firmness. They can also increase the ability of the skin to produce new elastin and collagen.

The Chemical Peel

This process also assists in skin rejuvenation. By application of a chemical peel on the problem area, once the chemical peel is removed it takes away all old dead skin cells revealing skin that is more youthful looking. The chemical peel is applied and left to dry and once set, peeled off. This procedure also stimulates skin to generate new cells.

Injections for Skin Rejuvenation

There are many instances in which people have undergone skin rejuvenation by means of injection and this has proved successful. It entails having Restylane and Collagen injected below the skin of problem areas to plump the skin, giving a fuller, more smooth appearance. Botox is also use, this blocks neural impulses that cause the skin to contract, the resulting "relaxation" lets the skin health naturally.

Why to Proceed with Caution

All of the procedures mentioned above have proved successful skin rejuvenation methods. However, there are some drawbacks; they are sometimes not effective on people with darker complexions and others might have distressing side effects. Always check with your doctor to secure a method that is perfect for you.

Nick Hurd writes about aging and baby boomer generation and how to not only cope with the changes, but live a very healthy and active life. www.youreover50.com [http://www.youreover50.com/] information for baby boomers and beyond. More information about skin care and wrinkles is available at Taking care of your skin in the sun [http://www.youreover50.com/ReducingWrinkles/]

You'll also find other senior related information like Motor homes and the traveling lifestyle for the over 50 crowd [http://www.youreover50.com/motorhomes]

copyright 2008 Nicholas Hurd all rights reserved

Article Source: http://EzineArticles.com/expert/Nicholas_Hurd/90142

© 2016 EzineArticles
All Rights Reserved Worldwide